

## **Review of Preprocessing Techniques for Fundus Image Analysis**

Shilpa Joshi, P. T. Karule

Y.C.C.E., Hingna, Nagpur 441110, India (ssjd10@gmail.com, ptkarule@gmail.com)

### **Abstract**

The principal target of preprocessing is to get more appropriate resultant image than its original for further additional analysis. Enhancement of retinal images creates several challenges. The main obstacle is to develop a technique to accommodate the wide variation in contrast inside the image. Necessity of preprocessing methods are for image normalization and to increase the contrast for achieving accurate analysis. This work examined literature in the prior process of digital imaging, in the field of the analysis of fundus image to extract normal and pathologic retinal traits within the context of diabetic retinopathy (DR).

### **Key words**

Color Space Conversion, Filtering, Contrast Enhancement, Shade Correction.

### **1. Introduction**

Normally, in the center of the image contrast of the fundus is high and diminishes with respect to the distance of pixel away from the center. Preprocessing minimizing this effect and to get the more uniform image by normalizing the mean intensity of an image. Retinal imaging generally affected by non-uniform illumination due to several factors such as the narrow lens in the completely dilated pupil, variation in light reflection and diffusion, noise, low contrast, differences in retinal pigmentation and differences in cameras, limitations of the instrument as the ring-shaped model illumination pattern and imaging related to variation in illumination axes of the eye with respect to optical axes. For the comparison of changes in images acquired at different times mostly affected by this spatially non-uniform illumination. The major factor for inhomogeneity, in terms of luminosity and contrast lies in the same image or between images. In

computer-assisted diagnostic system preprocessing play a vital role for precise extraction of various characteristics and diagnosis of DR according to the analysis of the fundus images.

## **2. Related Work**

The compensation of image variability is essential to result in meaningful brightness information. To target this problem, the retinal background area was analyzed to detect changes of luminosity, contrast and through an estimation of their local statistical properties, derives a compensation for their drifts. Three of the parts belong to preprocessing: color space conversion along with Shade correction, color normalization and poor image quality detection through illumination equalization and filtering. The preprocessing techniques used in the previous articles of the fundus images are shortly discussed in the following section.

### **2.1 Color Space Conversion and Normalization**

The color modes used for fundus image analysis are as follows. RGB bands intensities are transformed to intensity -hue -saturation representation. The RGB and HSI color models are invertible. This results in only processing of intensity of the pixels instead of its perceived relative color values. As HSI model provides decoupling of intensity from color component of an image. Local contrast enhancement of these intensity components only proves beneficial in image enhancement and conversion of it to RGB is provided without disturbing the color content of image pixels. It is closer to the way a human experiences color and removal of noise in HSI color space. HSI Color space conversion has adopted by Sopharak et al. [1-2]. Median filtering and a zero and edge padding removal on I band of HSI model has employed in [3]. On the intensity values of HIS color model, local adaptive contrast techniques result in intensity normalization and contrast enhancement as proposed by Usher et al. [4]. But the adverse effect of this technique is that along with adjustment of contrast sometimes noise may also increase. Median filtering and CLAHE on I band of HIS has proposed in [5]. The HSV color system is another color system similar to HSI. Both the HSI and HSV color systems can be used in a similar way in color image segmentation. Adaptive histogram equalization on HSV color space conversion was applied in [6]. Brightness correction on HSV color model, Gaussian algorithm and CLAHE proposed in [7]. RGB to YIQ color conversion results in overall improvement in color saturation and in the contrast between lesions and background as proposed by Sanchez et al. [8]. RGB to YIQ is suitable component for retinal image analysis by Haniza et al. [9]. Contrast enhancement of lesions attributes and overall image color saturation in [10]. Adaptive histogram equalization was applied to M band of CMY color space [11]. Preprocessing consist of RGB to CIE Lab color

space conversion was given in [12]. The variation is correlated with the skin pigmentation and iris color of the different person. Color normalization is achieved by combining the normalized R, G and B components. CIE color model allows separation of intensity from two other color components make it more appropriate for enhancement. To carry out preprocessing algorithm only on circular fundus and not to hinder by background pixels, the detachment of fundus with respect to its background employed as one of the major important steps of preprocessing. A comparison between grey world normalization, color histogram equalization and color histogram specification to a standard image was undertaken by Goatman et al. [13]. Osareh et al. [14] used the same approach after color normalization of fundus images using histogram specification. After conversion of RGB to HIS, only on intensity I channel of HIS, this operation was applied so that color attributes of the image would not affect [15-16]. Color normalization not finding true object color but aims to transform the color, which is invariant with respect to illumination changes having the ability of differentiation between ROI.

## **2.2 Shade Correction**

In color fundus images the main challenge is the presence of noise at some level; to address this problem most of the previous literature have based on median filtering and convolution with smoothing kernels. Small intensity variations in the green-plane image background are removed in the preprocessing step resulting in a “shade corrected” image. This shade correction is accomplished by subtracting the background image from the green image. The background image was estimated by smoothing the green image with a median filter. 56x 56 median filter was employed by Lee et al. [17] to get shade corrected image. A shade-corrected image has also used in [18-20]. The background image produced by smoothing the original image with a low-pass filter or a mean or median filter whose size is greater than the largest retinal feature. 3 x 3 mean filters in combination with Gaussian kernel were applied for shade correction in [21]. The goal of preprocessing steps was employed using a noise cleaning to avoid aberrant pixels due to the inadequate method of transferring image followed by a smoothing step and finally, normalization was applied as a shade correction method [22]. AHE and median filtering along with the thresholding were proposed to get shade corrected image [23].

## **2.3 Adaptive Contrast Enhancement**

In an image low intensity pixel represent interested objects among several objects present in an image. To identify those objects these minimum intensity criteria have used. Local contrast

enhancement is a histogram-based contrast enhancement method [24] in which the brightness across the whole image is flattened, tending to enhance the darker and not to over expose the brighter areas. Simple histogram equalization may tend to degrade the image by over enhancing certain areas, which leads to information loss in both the brighter and darker areas of the image and to blur of the retinal details. Bright regions will tend to become over exposed and areas of the low signal will tend to become darker. The introduction of local contrast enhancement eliminated these problems by dividing the image into relatively small areas with similar contrast. Each area has then enhanced appropriately. For further analysis of retina images, several illumination equalization preprocessing methods in terms of histogram processing such as equalization and specification considerably increases the contrast and illumination. A preprocessing module encompasses four steps such as enhancement; contrast limited adaptive histogram equalization (CLAHE), brightness preserving dynamic fuzzy histogram equalization (BPDFHE) and de-correlation stretching. BPDFHE provides few functional steps to have contrast improved image by passing low contrast image. CLAHE is a popular technique in the biomedical image processing because it is very effective in forming normally to interesting leaping out parts that are more visible. Splitting the image into disjoint regions and local histogram equalization is applied in each region followed by elimination of boundaries between the regions through bilinear interpolations [25]. In [26] preprocessing was applied as Illumination equalization and CLAHE. Normally effect of “Vignetting” was observed in retina images. As brightness diminishes over the edge causes contrast reduction over it. Illumination equalization method overcomes this effect and use of CLAHE results in the removal of noise present in an image. To improve the contrast of fundus images grey level transformation was proposed by Sinthanayothin et al [27]. Preprocessing algorithms distinguished bright objects from the background. This research started with the development of preprocessing techniques to improve image quality. Adaptive contrast enhancement was first proposed in [28] in order to emphasize features in the retinal image. The mean and variance of the intensity within a sub local region were considered and the transformation function was applied. The non-uniform illumination correction was provided by dividing the image by an over-smoothed version of it using a spatially large median filter [29]. Preprocessing method proposed in [30] makes the reduction in uneven illumination across the retinal images. In [31] the grey levels have normalized using CLAHE to visualize the hiding features. High contrast and well-balanced level of overall brightness in the images gives the characterization of the high quality of the image. Zhang et al. [32] was applied adaptive local contrast enhancement to sub-image areas using the local mean and standard deviation of intensities for the detection of bright DR areas from fundus images. Intensity properties as

standard contrast stretching techniques have applied by [33-34] for segmentation and noise reduction. Wang et al. [35] used brightness transform function similar to gamma correction to adjust the image brightness. Illumination was equalized by AHE followed by Gabor standard deviation filter in [36]. Adaptive local contrast enhancement was applied in [37], rescaled pixels to the full intensity range. Walter and Klein [38] contrast enhancement method results in smooth background grayscale image and emphasized on salient parts. Grayscale diameter closing [39] aims to get possible candidate extraction. Illumination equalization was also employed in [40]. Fundus images were contrast enhanced in order to obtain sharp edges and transformed to correlation coefficient images by the use of two sets of Gaussian Kernel patches with distinct scales of resolution [41]. The proposed algorithm of CLAHE was adopted to enhance the contrast of the image by divide and conquers approach to result in overcoming of the global noise from the images [42]. The digital color fundus image has pre-processed using AHE [43] and was enhanced by applying Top hat and Bottom hat transforms [44]. The aim of preprocessing has achieved by applying AHE to compliment of green channel image and then morphology to normalize the image followed by median filtering and double background subtraction [45].

## **2.4 Background Exclusion**

The main purpose of this step is eliminating background variations in illumination from an image so that the foreground objects can be analysed more easily. The background exclusion is performed by subtracting the original intensity image from the average filtered image. The majority of fundus images have backgrounds which change the image. This effect is partially due to illumination angles, partially due to the flash glare and also to the natural variation of the retina appearance. Grisan et al. [46] have improved the previous technique by employing a mathematical model of the background illumination and noticing that contrast normalization negatively affects lesion segmentation algorithms. Background removal using average filtering, salt and pepper noise removal using median filtering and AHE was proposed in [47]. Foracchia et al. [48] were reported luminosity and contrast enhancement using an adaptive calculation of contrast by first identifying pixels which has likely to belong to the background retina. Foreground and background separation were achieved through the estimation of uniform luminosity and standard deviation [49]. Luminosity and contrast normalization Foracchia method was also applied in [50]. A foreground image, background image and its acquisition function were proposed by several authors [51-52] through image formation models for describing observed fundus image. Modified valley emphasized automatic thresholding and morphology for color distorted background exclusion was adopted in [53]. Undesired background separation

through morphology and edge operator as preprocessing was proposed in [54]. Median filtering, CLAHE, Bottom hat and contrast stretching for background removal [55], median filtering and bottom hat for background separation [56], CLAHE, thresholding, background exclusion and post filtration [57] have reported.

## 2.5 Filtering

The use of the selected preprocessing methods aims to enhance the accuracy of the lesion detection in different ways. Yet, the technique of contrast increase improves not only the image, but improves also the picture contains noise. Hence, a smoothing technique is introduced first, which aims to suppress noise or other small fluctuations in the image. The smoothing method used median filtering which reduces the blurring of edges within the image. The idea is to replace a given point in an image by the median of the brightness in its neighborhood, instead of by the average. The median of the brightness in the neighborhood unaffected by individual noise spikes. The elimination of impulsive noise results through median smoothing. Furthermore, median filtering does not blur the edges as its objective is to achieve noise reduction rather than blurring. Median filtering is better in the state to remove these outliers without making the reduction in the sharpness of the image. The median filter has a benefit of simultaneously reducing noise and preserving edges [58]. Fleming et al. [59] were used a 3x3 median filter to remove salt-and-pepper noise. In order to extract candidates, this method constructs a maximal correlation response image for the input retinal image [60]. A better contrast was obtained by Gaussian filtering the resultant image. These methods have applied separately to the red, green and blue components of the RGB color values of the Image [61]. Pixel-wise cross-sectional profiles with multiple orientation was used for the computation of multi directional height map by Lazar et al. [62]. This map results in the assignment of the row of height values to describe pixel and its surroundings differentiation in a spatial direction. Spencer et al. [66] and Frame et al. [67] proposed one of the novel popular algorithms for extraction of candidates. The subtraction of maximum response of multiple top hat morphology transformed result was accomplished to get true candidates. Applications of Gaussian filter results in binarization. In this algorithm Gaussian matched filter results in smoothing. The map smoothens by the use of hysteresis thresholding and an averaging kernel. Finally, according to the size, resulting components are filtered. Before abnormal lesions have searched from an acquired fundus image, the image has pre-processed to ensure the adequate level of success in the abnormality detection [68]. In fact, median filtering is general enough to take into account the natural change in the retinal appearance in addition to the luminosity changes. The median is a non-linear filter, which reduces the impulsive distortion in an image and without too much

distortion at the edges of an image. The advantage of a median filter consists in the fact that it is very robust and has the capability to filter only outliers and is thus an excellent choice for the elimination of horizontal scanning artifact, especially salt and pepper noise. The combined method of histogram equalization and smoothing filter results in contrast enhancement of retinal image utilized in [69]. In [70-73] a large mean filter, large median filter, or both have used for estimating the fundus background. The median filtering and CLAHE applied on the green channel of the image to reduce the image noise and to improve the quality was adopted in [74] so that the image features become easier to detect in the automated fundus image analysis system. Preprocessing of the image was applied in terms of median filtering and CLAHE on complemented green channel image [75]. Preprocessing was employed for grey level homogenization, median filtering and thresholding [76]. Low pass filtering is the other type of approach results in correction of non-uniformly illumination. The main issue related to this technique is the filter's cut off frequency value for the removal of non-uniformly of the illumination without affecting the image details. Preprocessing in terms of grayscale estimation and GSZ shock filter was proposed [77]. Gabor wavelet along with sharpening filters to enhance vascular pattern employed in [78]. Convolution with fourteen digital filters was proposed by Niemeijer et al. [79].

## **2.6 Morphological Processing**

Mathematical morphology in image processing is particularly suitable for analyzing shapes in images through two main processes, dilation and erosion. On a grey level image, dilation brightens small dark areas. Erosion makes small bright areas as smaller or noise spur dark. The algorithms opening with an element of some form of structuring can separate objects in an image, while preserving image structures that can contain the structural element and remove those who are not. Closing has accustomed to 'fill-in' small holes within an image. Algorithms combining the above processes are used to create mechanisms of edge detection for noise removal and background removal as well as for finding specific shapes in images. The transformation of the Morphological top hat is a strong technique for image improvement, particularly in the extraction of bright qualities in the dark background [80-84], With the adaptation of, size of structuring element more than the maximum value of vessel scale results in suppression of non-vascular structures in fundus images. Walter et al. [85] have suggested a mathematical morphology supported approach, which recommends contrast improvement and shade correction as preprocessing steps. The treatment of morphological picture exploits characteristics of the form of vasculature which are a priori known, as it being piecewise linear and linked. Morphological operations play a vital role in digital image

processing which goes with a special application in the field of machine vision and automatic object detection in procession [86]. Multiscale morphological operations for vessel enhancement reported in [87]. Giancardo et al. [88] was proposed morphological reconstruction for enhancement of vessel like structures. Mathematical Morphology process in terms of opening and reconstruction operation with Top hat transform as well as Gaussian filtering was proposed for smoothing or removing any noise [89-90]. Top- hat transform and median filtering on the green component of the image was employed in [91]. Hybrid morphological reconstruction technique was adopted in [92]. Preprocessing consists of image enhancement based on HE morphological operator followed by binarization [93], AHE and morphology [94] has reported.

## **2.7 Mask Generation**

A fundus image consists of a circular fundus and a dark background surrounding the fundus. Exclusion of background pixels and processing of only the fundus pixels provides with the use of fundus mask. The mask is defined as “a binary image of the same resolution of the fundus image whose positive pixels correspond to the foreground area”. Mask of the fundus camera has different size and shape according to its settings. Knowing which pixels belong to the retina is a step that helps subsequent analysis to give information about the effective size and shape of the image that has analyzed. Median filter results in the removal of noise from the resultant fundus mask and morphological opening results in the removal of edge pixels. Thereafter, the mask is acquired by extracting pixels having the values greater than 0 over the range of 0 – 255, then FOV will accept 255 by multiplying the picture of the mask with the biggest value in pixels. The initial detection of the mask is particularly important. Various cameras employ masks of different sizes and parameters will be inaccurate if the ratio between the mask and real retina size varies. The mask is extracted employing the green plane with 256 levels. A binary image containing all the pixels less than a threshold set to 10 levels more than the minimum value is created. Preprocessing has applied in the steps of green channel extraction, mask generation and dilate borders and CLAHE image enhancement [95]. Automatic mask generation was employed to avoid processing of the black border in the images in [96-97]. Thresholding and morphological operations based technique fail to give a perfect mask when the fundus image is not well exposed. Image processing tool like ImageJ software has proposed to generate mask [98]. A new automatic method for preprocessing was proposed to generate a binary mask using the Gaussian filter to define the region of interest [99]. Bright artifacts mask generation was applied on blue channel of fundus image obtained by using the sixth quantile which estimates the threshold for distribution [100]. Thresholding and



morphological operations on image red band using 3x3 square kernels to get final ROI mask followed by AHE was proposed by [101]. HE and thresholding function has employed for mask generation [102-103]. Mean filtering, retinal mask generation and illumination correction in [104].

Other authors seem to have preprocessing operations which included spatial normalization and the preprocessing by [105], masking ROIs by Hoover et al. [106] and Leandro et al. [107], Ye and Zheng et al. [108] employed noise suppression algorithm. A simpler approach was used by Shin et al. [109], Lee et al. [110], mean normalization [111], Gaussian Pyramid and efficient neighborhood analysis [112] and Ege et al. [113], all used a 31 pixels squared median-filter as a smoothing operator in order to obtain a representation of the image, mentioning that the picture is of low frequency content. This image was then subtracted from the original to remove the effect of unequal or irregular illumination. Marwan et al. [114] was adopted four different steps for preprocessing. Several illumination correction techniques are based on AHE, Gamma correction, Gamut mapping [115], and Retinex based algorithms [116-117], linear and nonlinear background correction [118], Grayscale conversion, fuzzy filtering, fuzzy HE, fuzzy edge detection [119-120], homomorphic filtering [121-124]. The application of median filtering, CLAHE, binarization steps and surface fitting proposed in [125-126]. Without the use of any contrast enhancement procedure optimal AM-FM results in true candidates extraction to prove as reliable algorithm to not only enhance the low intensity of the images but also extraction of multiple features to detect actual candidates through classification in [127-128]. First white top hat transforms the geodesic detection followed by color histogram thresholding is the sequential steps provided in preprocessing module by [129]. Goatman et al. [130] proposed a method for contrast enhancement in which the image contrast stretching was used to cover full pixel dynamic range excluding the dark surrounding border pixels for normalization. Histogram thresholding was used in [131]. Image enhancement reported by applying decorrelation stretching with the increase in difference of hue measure [132]. Fast discrete curvelet transform via wrapping method was applied and reconstructed the image using modified coefficient [133]. Image enhancement based on lifting scheme version of D4 wavelet transform was proposed in [134]. Edge detection through Sobel operator followed by color compression using K-means clustering to emphasize on lesions proposed in [135]. The author of [136-137] proposed iterative homographic surface fitting for the compensation of non-uniform illumination. Gabor wavelet on the inverted green channel was proposed in [138]. Brightness Area Product for normalization and image subtraction for contrast enhancement [139]. Principal component analysis, image enhancement and inpainting algorithm as a preprocessing reported in [140]. Figure 1 shows the frequency of distribution of the various preprocessing techniques.

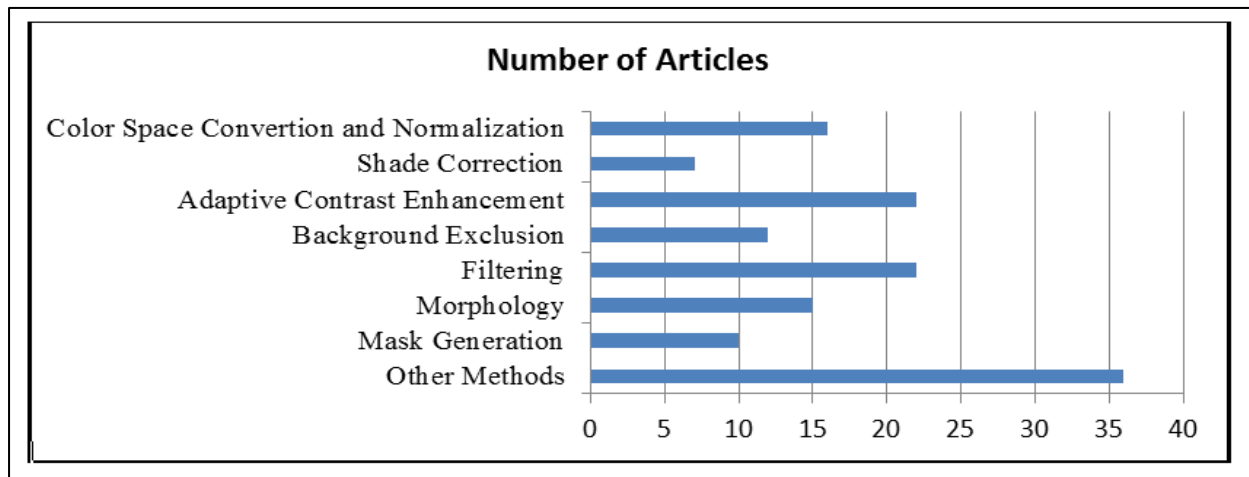


Fig.1. The Frequency Distribution of various Preprocessing Methods

## 2.8 Conclusion

Image preprocessing can do both improving qualities of the image and play a central role in improving the accuracy of features detection task (normal and abnormal). In this paper, we have discussed the wide variety of technique to provide high quality records of fundus appearance which have the potential to improve fundus image analysis and accurate diagnostic in automated in DR system.

## References

1. A. Sopharak, A. Uyyanonvara, S. Barmanb, Williamson, Automatic detection of diabetic retinopathy exudates from non-dilated retinal images using mathematical morphology methods, 2008, Computerized Medical Imaging and Graphics, pp. 720–727.
2. A. Sopharak, A. Uyyanonvara, Automatic Exudates Detection from Non-Dilated Diabetic Retinopathy Retinal Images using Fuzzy C-means Clustering, 2009, Sensors, pp. 2148-2161.
3. M. Iqbal, A. Aibinu, Detection of Vascular intersection in retinal fundus Image using Modified Cross point number and NN Technique, 2008, Int. Conf. Comp. Comm. Engg, pp. 241 - 246.
4. D. Usher, Dumskyi, Wiiamson, Nussey, Automated detection of diabetic retinopathy in digital retinal images: Tool for diabetic retinopathy screening, 2004, Diabet Med Engg, 21, pp 84-90.
5. G. Nayomi, R. Ranamuka, N. Gayan, Meegama, Detection of hard exudates from diabetic retinopathy images using fuzzy logic, 2013, IET Image Processing, Vol. 7, 2, pp. 121–130.
6. P. R. Asha, S. Karpagavalli, Diabetic Retinal Exudates Detection Using Extreme Learning Machine, 2015, Emerging ICT for Bridging the Future, pp. 1-5.

7. J. P. Bae, K. G. Kim, H. C. Kang, C.B. Jeong, K. Park, A study on Hemorrhages detection using Hybrid method in fundus Images, 2010, Journal of Digital Imaging, pp. 394-404.
8. C. Sanchez, A. Mayo, M Garcia, A. Hornero, Automatic Image Processing Algorithm to Detect Hard Exudates based on Mixture Models, 2006, IEEE EMBS Annual Int. Conf, pp. 4453-4456.
9. H. Yazid, H. Arof, N. Mokhtar, Edge Sharpening for Diabetic Retinopathy Detection, 2010 IEEE Conf. on Cybernetics and Intelligent Systems, pp. 41 - 44.
10. C.I. Sanchez, Poza, Retinal Image Analysis to Detect and Quantify Lesions Associated with Diabetic Retinopathy, 2004, Int. Conf. on Eng. in Medicine and Biology, pp. 1624–1627.
11. M. Lotankar, K. Noronha, J. Koti, Detection of Optic Disc and Cup from Color Retinal Images for Automated Diagnosis of Glaucoma, 2015, UPCON, pp.1-6.
12. S. Kavitha, K. Duraiswamy, Automatic Detection of Hard and Soft Exudates in Fundus Images Using Color Histogram Thresholding, 2011, European J. of Scientific Research, pp.493-504.
13. K. Goatman, A. Whitwam, A. Manivannan, J. Olson, A. Sharp, Color normalization of retinal images, 2003, Int. Proceeding medical image understanding and analysis, pp. 149-152.
14. A. Osareh, M. Mirmehdi, B. Thomas, R. Markham, Automated identification of diabetic retinal exudates in digital color images, British Journal of Ophthalmology, 2003, no. 87, pp. 1220–1223.
15. A. Osareh, M. Mirmehdi, B. Thomas, Markham, Classification and localization of diabetic-related eye disease, 2002, 7th European Conference on Computer Vision, pp. 502-516.
16. A. Osareh, Automated Identification of Diabetic Retinal Exudates and the Optic Disc, PhD thesis, Department of Computer Science, University of Bristol, 2004.
17. S. Lee, Y. Wang, Computer algorithm for detection and quantification of microaneurysms and hemorrhages in color retinal images, 1999, Int. Conf. Image Perception Performance, pp.61-71.
18. M. Cree, E. Ganble, D. Cornforth, Color normalization to reduce inter-patient and intra-patient variability in microaneurysms detection in color retinal images, 2005, WDIC ARPS workshop on digital image computing Brisbane, Australia, pp.163-168.
19. H. Hipwell, Strachan, Olson, McHardy, Sharp, Automated detection of microaneurysms in digital red-free photographs: a diabetic retinopathy screening tool, 2000, Diabetic. Med, pp. 588-594.

20. B. Dupas, T. Walter, A. Erginay, et al., Evaluation of automated fundus photograph analysis algorithms for detecting microaneurysms, HEs and exudates and of a computer-assisted diagnostic system for grading diabetic retinopathy, *Diabetic. Metab*, 2010, vol.36, pp.213-220.
21. V. Shanmugam, W. Banu, Retinal blood vessel segmentation using an extreme learning machine approach, *IEEE 2013, Point-of-Care Healthcare Technologies*, pp. 318 –321.
22. P. Badea, D. Dnciu, Preliminary rules on using extension of gradient method for detection red lesions on fundus photographs, *Aut. quality testing robotics, IEEE 2008, Int. Conf.* pp 43-48.
23. V. Mane, D. Jadhav, Ramish, Preprocessing in Early Stage Detection of Diabetic Retinopathy Using Fundus Images, 2015, *Adv. of Med. Electronics, Lecture Notes Bioengg*, pp. 27-38.
24. R. C. Ganzalez and R. E. Woods, *Digital image processing, Second edition. Prentice Hall: New Jersey, 2001.*
25. K. Zuiderveld, Contrast limited adaptive histogram equalization, 1994, *Graphics Gems, vol. 4*, pp. 474–485.
26. T. Yamuna and S. Maheswari, Detection of abnormalities in retinal images, *ICECCN IEEE 2013*, pp. 236-240.
27. C. Sinthanayothin, Boyce, Williamson, Automated localization of the optic disk, fovea and retinal blood vessels from digital color fundus images, 1999, *British Journal Opth.* 902–910.
28. C Sinthanayothin, K. Viravud, P. Suthee, S. Apichart, Automated screening system for diabetic retinopathy, 2003, *International Symp. on Image and Signal Processing Analysis*, pp. 915–920.
29. G. Yang, S. Wang, I. Gagnon, Boucher, Algorithm for detecting microaneurysms in low resolution color retinal images, 2001, *In Proc. Vision Interface 21*, pp. 139-142.
30. A. Youssif, Ghoneim, Comparative study of contrast enhancement and illumination equalization methods for retinal vasculature segmentation, 2006, *Int. Biomed. Engg. Conf.*, pp.21-24.
31. U. Akram, A. Tariq, S. Nasir, Automated Retinal Images: Noise Segmentation, *IEEE 2008, Int. Multitopic Conference*, pp. 23-24.
32. X. Zhang, O. Chutatape, S. Nemeth, P. Soliz, Detection and classification of bright lesions in color fundus images, 2004, *Int., Conf. on image processing, vol. 1, 53(6)*, pp. 139-142.

33. M. H. Goldbaum, N. P. Katz, S. Chaudhuri, M. Nelson, P. Kube, Digital image processing for ocular fundus images, 1990, *Ophthalmology, Clinical North American*, vol. 3, pp. 756–760.
34. S. Lee, E. Lee, Y. Wang, Comparison of diagnosis of early retinal lesions of DR between computer system and human experts, 2001, *Gra. Arch. Clin. Exp. Opht.* vol. 119, pp. 509–515.
35. H. Wang, W. Hsu, K. Goh, M. L. Lee, An effective approach to detect lesions in color retinal images, 2000, *IEEE CVPR*, pp. 181–187.
36. D. Wu, M. Zhang, J. Liu, W. Bauman, On the adaptive detection of blood vessels in retinal images, 2006, *IEEE Transaction on Biomedical Engineering*, vol.53, no. 2, pp. 341–343.
37. A. Osareh, M. Mirmehdi, Automatic recognition of exudative maculopathy using FCM and neural networks, 2001, *Medical Image Understanding and Analysis*, pp. 49–52.
38. T. Walter, J. Klein, Automatic detection of microaneurysms in color fundus images of human retina by means of the bounding box closing, 2002, *Lecture Notes in Comp. Sci* pp.210-220.
39. T. Walter, P. Massin, A. Arginay, R. Ordonez, C. Jeulin, J. Klein, Automatic detection of microaneurysms in color fundus images, 2007, *Med. Image Anal.*, vol. 11, pp. 555–566.
40. F. Haar, Automatic localization of the optic disc in digital color images of the human retina, 2005, M.S. Thesis, Utrecht University.
41. M. Himaga, D. Usher, Retinal Blood Vessel extraction by using multi-resolution matched filtering and directional region growing segmentation, 2002, *IAPR machine vision appl.*, pp. 529–51.
42. V. Raman, P. Then, P. Sumari, Automatic Hemorrhages detection based on fundus images, 2016, 7th IEEE Conf., on information technology and electrical Engg., pp 253-258.
43. J. Nayak, P. Subbanna, Bhat, R. Acharya, C. M. Lim, M. Kagath, Automated Identification of Diabetic Retinopathy Stages Using Digital Fundus Images, 2007.
44. K Saranya, B Ramasubramanian, S. Mohideen, A novel approach for the detection of new vessels in the retinal images for screening diabetic retinopathy, 2012, *ICCSP*, pp. 57–61.
45. J. Dash, N Bhoi, A Survey on Blood Vessel Detection Methodologies in Retinal Images, *Int. Conf. on Computational Intelligence and Networks*, 2015, 2375-5822/15 IEEE.
46. E. Grisan, A. Giani, Ceseracciu, Ruggeri, Model-based illumination correction in retinal images, 2006, *Int. Symposium on Biomedical Imaging: Nano to Macro* 984–987.
47. A. Pandey, R. Chandra, M. Datta, R. burget, J. Minar, Automatic Detection of Red Lesions in Diabetic Retinopathy using Shape based Extraction Technique in fundus image, *IEEE*

- 2016, 39th Int. Conference on Telecommunications and Signal Processing TSP, pp. 756–760.
48. M. Foracchia, E. Grisan, A. Ruggeri, Luminosity and contrast normalization in retinal images, 2005, IEEE Transaction on Medical Imaging. Analysis, no. 9, pp. 179–190.
  49. D. Zhang, X. Li, X Shang, Y Yi, Y Wang, Robust Hemorrhage detection in diabetic retinopathy image, IEEE (2012), pattern Recognition ACPR, pp. 756–760.
  50. M. Garcia, I. Sancheza, M. Lopezb, D Abasoloa, R. Horneroa, Neural network based detection of hard exudates in retinal images, 2009, Comp methods and prog. in biomedicine, pp.9–19.
  51. M. J. Cree, J. A. Olson, P. Sharp, V. J. Forrester, The preprocessing of the retinal image for the detection of fluorescein leakage, 1999, Physics in Medicine and Biology, pp. 293.
  52. M. Foracchia, E. Grisan, A. Ruggeri, Detection of optic disc in retinal images by means of a geometrical model of vessel structure, 2004, IEEE Trans. on Medical Imaging, pp. 1189–1195
  53. N. Mukherjee, H. Dutta, A New Approach for Color Distorted Region Removal in Diabetic Retinopathy Detection, 2015, Adv. of Medical Electronics, Lecture Notes in Bioengineering.
  54. J. Sivakamasundari, V. Natarajan, Proposal of a CBIR Framework for Retinal Images Using Fusion Edge Detection and Zernike Moments, 2015, SEMCCO, LNCS 8947, pp. 738–749.
  55. M. Fadzil, L. Izhar, H. Nugroho, Determination off avascular zone in diabetic retinopathy digital fundus images, 2010, Computers in Biology and Medicine 40, pp. 657–664.
  56. K. Ram, G. Joshi, and J. Sivaswam, A Successive Clutter-Rejection based Approach for Early Detection of Diabetic Retinopathy, 2011, IEEE Trans. on Biomedical Engineering, pp. 1-9.
  57. D. Marwan, C. Eswaran, A Mueen, An Automated Blood Vessel Segmentation Algorithm Using Histogram Equalization and Automatic Threshold Selection, 2010, J. of Digital Imaging
  58. K. Oktoeberza, H. Nugroho, T. Adji, Optic Disc Segmentation Based on Red Channel Retinal Fundus Images, 2015 ICSIIT, CCIS 516, pp. 348–359.
  59. B. Zhang, X. Wu, J. You, Q. Li, F. Karray, Detection of microaneurysms using multi-scale correlation coefficients, 2010, Pattern Recognition, vol. 43, no. 6, pp. 2237–2248.
  60. J. Anitha, D. Selvathi, D. Jude, Hemanth, Neural Computing Based Abnormality Detection in Retinal Optical Images, IEEE 2009, Int. Advance Computing. Conf. pp. 6-7.
  61. I. Lazar, A. Hajdu, Microaneurysms detection in retinal images using a rotating cross-section based model, 2011, Proc. IEEE Int. Symposium Biomedical Imaging, pp. 1405–1409.

62. A. Fleming, S. Philip, Goatman, Automated microaneurysms detection using local contrast normalization and local vessel detection, 2006, IEEE Trans on Med. Imaging, pp. 1223–1232.
63. S. Abdelazeem, Microaneurysms detection using vessel removal and circular Hough transform, 2002, National Radio Science, Conf. pp.421– 426.
64. H-SNam, J. M. Hwang, H. Chung, J-M Seo, Automated measurement of retinal vessel diameters on digital fundus photographs, WC 2009, IFMBE Proc, pp.277-280.
65. E Grisan, Thesis, Automatic Analysis of Retinal Images: Retinopathy Detection and Grading.
66. T. Spencer, Olson, K. C. McHardy, Sharp, J. V. Forrester, An image-processing strategy for the segmentation and quantification of microaneurysms in fluorescein angiograms of the ocular fundus, 1996, Computer Biomed. Res., vol. 29, pp. 284–302.
67. A. Frame, Undrill, Cree, Olson, McHardy, P. Sharp, Forrester, A comparison of computer based classification methods applied to the detection of microaneurysms in ophthalmic fluorescein angiograms, 1998, Computers in Bio. and Med, pp. 225 238.
68. I Lazar, R. Hajdu, R. Quareshi, Retinal microaneurysms detection based on intensity profile analysis, 2010, 8th International Conference on Applied Informatics, pp.1405 – 1409.
69. M. Tamilarasi, K Duraiswamy, Genetic based fuzzy seeded region growing segmentation for diabetic retinopathy images, 2013, ICCCI International Conference on. IEEE, pp.1–5.
70. M. Akram, S. Khalid, S. Khan, Identification and classification of microaneurysms for early detection of diabetic retinopathy, 2012, Pattern recognition, pp. 1–10.
71. G. Urcid, Lara-R L.D, Lopez-M E., Pathologies Segmentation in Eye Fundus Images Based on Frequency Domain Filters. WCECS 2015, Transactions on Engg. Technologies, pp. 137-151.
72. N. Ward, S. Tomlinson, C. Taylor. Image analysis of fundus photographs. 1989, Ophthalmology, 96, pp. 80–86.
73. R. Phillips, F. John, P. Sharp. Automated detection and quantification of retinal exudates, 1993, Graefe's Archive for Clinical and Experimental Ophthalmology, vol. 231, pp. 90–94.
74. S. Sreng, N. Maneerat, I. Don, Automatic hemorrhages detection based on fundus images, 2015, ICITEE, pp. 253 – 257.
75. M. Paing, C. Somsak, R. Yodprom, Detection of lesions and Classification of Diabetic Retinopathy using Fundus Images, IEEE 2016, Bio Med. Int. Conf., pp: 573 – 577.

76. M. Preethi., R. Vanithamani, Review of Retinal Blood Vessel Detection Methods for Automated Diagnosis of Diabetic Retinopathy, IEEE- 2012, conf. ICAESM -2012, pp. 262 – 265.
77. S. Kumar, Madheswaran, Extraction of Blood Vascular Network for development of Automated Diabetic Retinopathy Screening, IEEE 2009 comp. tech. and development, vol. 2, pp. 360-64.
78. A. Akram, A. Tariq, S Nasir, S Khan, Gabor Wavelet based vessel segmentation in Retinal Images, 2009, IEEE Symp. on Computational Intelligence for Image Processing, pp. 116 – 119.
79. M. Niemeijer, B. Ginneken, Russell, Abramoff, Automated detection and differentiation of drusen exudates and cotton wool spots in digital color fundus photographs for diabetic retinopathy diagnosis, 2007, Investigative Ophthalmology Visual Science, pp. 2260-2267.
80. S. Mukhopadhyay, B. Chanda, Multiscale morphological approach to local contrast enhancement, 2000, Signal Processing, vol. 80, no.4, pp.685–696.
81. A. Mendonca, A. Campilho, Segmentation of retinal blood vessels by combining the detection of centerlines and morphological reconstruction, 2006, IEEE Transaction on Medical Imaging vol.25, no.9, pp.1200–1213.
82. P. Tang, H. Liu, K. Sun, Enhancement of coronary angiogram by estimation of local background in Medical Imaging, Parallel Processing of Images, and Optimization Techniques Proc. SPIE 6789, MIPPR 2007.
83. X. Bai, F. Zhou, B. Xue, Image enhancement using multi scale image features extracted by top-hat transform, Optics & Laser Technology, 2012, vol. 44, Issue 2, pp. 328–336.
84. X. Bai, Mineral image enhancement based on sequential combination of toggle and top-hat based contrast operator, 2013, Micron, vol.44, pp.193–201.
85. T. Walter, J. Klein, Segmentation of color fundus images of the human retina, 2001, 2nd Int. Symposium on Medical Data Analysis, pp. 282–287.
86. D Marin, A. Aquino, M. Arias, J. Manuel Bravo, A new supervised method for blood vessel segmentation in retinal images by using gray-level and moment invariants-based features, 2011, IEEE Transactions on Medical Imaging, vol. 30, no. 1, pp. 146–158.
87. K. Sun, Z. Chen, Y. Wang, Morphological multiscale enhancement, fuzzy filter and watershed for vascular tree extraction in angiogram, 2011, Journal of med. systems, vol. 35,5, pp. 811-24.
88. L. Giancardo, Y. Li, K. Tobin, E. Chaum, Automatic retina exudates segmentation without a manually labelled training set, 2011, Biomed Imaging Nano to Macro, IEEE pp. 1396–1400.



89. S. Ravishankar, A. Jain, A. Mittal, Automated feature extraction for early detection of diabetic retinopathy in fundus images, 2009, IEEE Conf. Comput. Vision Pattern Recog, pp. 210–217.
90. G. Hassana, N. Bendary, A. Hassanien, A. Fahmy, A. Shoeba, V. Snasel, Retinal blood vessel segmentation approach based on mathematical morphology, 2015, ICCMIT vol.65,pp. 612-622
91. D. Youssef, N. Sollouma A. El-dib, New feature based detection of Blood Vessels and Exudates in fundus Image, Image Processing Theory, tools and Application, 2010, IEEE pp. 294-299.
92. S. Fahimuddin, A. Sharma, S. Ahmed, Hybrid model for analysis of abnormalities in diabetic cardiomyopathy and diabetic retinopathy related images, 2016, Springer Plus 20165:507.
93. Y. Wong, U. Acharya, Y. Venkatesh, C. Caroline, Identification of different stages of diabetic retinopathy using retinal optical images, 2008, Information Sciences 178, pp.106-121.
94. A. Gonzalez, D. Kaba, Y. Li, X. Liu, Segmentation of the Blood Vessels and Optic Disk in Retinal Images, 2014 IEEE Journal of Biomed. And Health Info. Vol. 18, 4, pp. 1874-1886.
95. A. Elbalaoui, M.Fakir, K.Taifi, Merbouha, Automatic Detection of Blood Vessel in Retinal Images, IEEE 2016, 13th Int. Conf. Comp. Graphics, Imaging and Visualization.
96. L. Gagnon, M. Lalonde, M. Beaulieu, M. Boucher, Procedure to detect anatomical structures in optical fundus images, 2001, SPIE Conf. on Medical Imaging pp. 1218–1225.
97. K. Englmeier, K. Schmid, M. Maurino, M. Porta, Bek, O. Larsen, Hejlesen, Multi-resolution retinal vessel tracker based on directional smoothing, 2002, 3(21): 230–237.
98. Santha Kumar, Rajkumar, Tandur, Novel method for Automatic generation of Fundus Mask, 2016, Image Info. Processing Conf. IEEE, pp. 147 – 151.
99. F. Hashim, N. Salem, A. F. Seddik, Preprocessing of Color Retinal Fundus Images, 2014, JEC-ECC IEEE, pp.190 – 193.
100. P. Porwal, M. Kokare, A novel Method to remove Bright Artifacts for Enhancing Lesion Detection in Retinal Images, 2017, Icon, SIP IEEE pp. 1–5.
101. A. Youssif, A. Ghalwash, Optic Disc detection from Normalized Digital Fundus Image by Means of Vessel's Detection Match Filter, 2008, IEEE Trans on Med Imaging, pp. 11-18.
102. P. Manjiri, M. Ramesh, R. Yogesh, S. Manoj, Automated Localization of Optic Disk, Detection of Microaneurysms and Extraction of Blood Vessels to Bypass Angiography, 2014, FICTA, Adv. in Intelligent System and Computing, pp. 579-587.

103. R. Chon, J. C. Suniel, Histogram-Based Masking Technique for Retinal Fundus Images, 2015, Ubiquitous Computing App. Wireless Sensor, Lect. Notes Electrical Engg pp. 561-567.
104. Y. Zheng, Daniel, An Automated drusen detection for classifying age related macular degeneration with color fundus photograph, 2013, IEEE Symp. Biomed. Imag., pp. 1448-51.
105. R. Welikala, M. Fraz, J. Dehmeshki, A. Hoppea, V. Tahb, S. Mann, Genetic algorithm based feature selection combined with dual classification for the automated detection of proliferative diabetic retinopathy, 2015, Computerized Medical Imaging and Graphics, vol 43, pp. 64-77.
106. A. Hoover, Kouznetzova, Goldbaum, Locating blood vessels in retinal images by piece-wise threshold probing of matched filter response, 2000, IEEE Trans. Med. Imag. 19(3): 203–210.
107. J. Leandro, Jr Cesar, Jelinek, Blood vessels segmentation in retina: Preliminary assessment of the mathematical morphology and the wavelet transform techniques, 2001, SIBGRAPI Brazilian Symp. on computer graphics and Image Processing, pp. 84–90.
108. D. Ye, L. Zheng, Fundus image processing and feature classification based on mathematical morphology, 2000, Canadian Med. and Bio. Engg. Conf., Vol. 2, pp. 1015–16.
109. D. Shin, R. Kaiser, M. Lee, J. Berger, Fundus image change analysis: Geometric and radiometric normalization, 1999, SPIE Conf. on Ophthalmic Technologies, pp. 129–136.
110. S. Lee, Identifying retinal vessel networks in ocular fundus images, Master's thesis, 1992, The University of New Mexico.
111. C. Agurto, V. Murray, H. Yu, Wigdahl, M. Pattichis, S. Nemeth, E. Barriga, P. Soliz, A Multiscale Optimization Approach to Detect Exudates in the Macula, 2014, IEEE Journal of Biomed Health Info. Vol. 18, No. 4, pp. 1328-1336.
112. A. Budai, R. Bock, A. Maier, J. Hornegger, Robust Vessel Segmentation in Fundus Images, 2013, Hindawi Pub. Corp. Int. Journal of Biomed. Imaging, Article ID 154860, pp. 11.
113. B. Ege, O. Hejlesen, O. Larsen, Møller, B. Jennings, Kerr, D. Cavan, Screening for diabetic retinopathy using computer based image analysis and statistical classification Comp. Methods and Programs in Biomedicine, 2000, 62(3),165–175.
114. D. Marwan, C. Eswaran, An automated blood vessel extraction algorithm in fundus images, 2012, Int. conference on Bioinformatics and Biomedicine, pp. 482-486.
115. G. Finlayson, S. Hordley, Improving gamut mapping color constancy, 2000, IEEE Transaction Image Processing, pp.1774–1783.
116. D. Jobson, Z. Rahman, and G. A. Woodell, Properties and performance of a center/surround retinex, 1997, IEEE Transaction Image Processing, vol. 6, no. 3, pp. 451–462.

117. T. A. Soomro, J. Gao, Study of the Noise Level in the Color Fundus Images, ICDS 2015, LNCS 9208, Data Science, pp. 159-168.
118. M. J. Carlotto, Nonlinear background estimation and changed election for wide area search, 2000, Opt. Eng., vol.39, no.5, pp.1223–1229.
119. S. Rahim, V. Palade, C. Jayne, Holzinge, Detection of Diabetic Retinopathy and Maculopathy in Eye Fundus Images Using Fuzzy Image Processing, BIH 2015, LNAI, pp. 379–388.
120. S Rahim, V Palade<sup>1</sup>, S. James, C Jayne, Automatic Detection of Microaneurysms for Diabetic Retinopathy Screening Using Fuzzy Image Processing, 2015, EANN CCIS pp. 69–79.
121. D. Toth, T. Aach, V. Metzler, Illumination-invariant change detection, 2000, IEEE Southwest Symp. Image Analysis Interpretation, pp 667-676.
122. Guillemaud, Uniformity correction with homomorphic filtering on region of interest, 1998, IEEE Conf. Image Processing, pp. 872–875.
123. B. Brinkmann, A. Manduca, R. Robb, Optimized homomorphic unsharp masking for MR grayscale inhomogeneity correction, 1998, IEEE Trans. Med. Imaging, vol. 17, 2, pp. 161-71.
124. J. Lou, H. Yang, W. Hu, T. Tan, 2002, An illumination invariant change detection algorithm, 5th Asian Conf. Computer Vision, Melbourne, Australia, pp. 1-6.
125. R. Jain, K. Skifstad, Illumination independent change detection from real world image sequences, 1989, Computer Vis. Graph. Image Processing, vol. 46, pp. 387–399.
126. Y. Plotnikov, N. Rajic, W. P. Winfree, Means of eliminating background effects for defect detection and visualization in infrared thermography, 2000, Opt. Eng., vol. 39, no. 4, pp.89-96.
127. J. Hajer, H. Kamel, E. Noureddine, Localization of the optic disk in retinal image using the “watersnake”, 2008, Int. Conf. on Computer and Communication Engineering, pp. 947 – 951.
128. A. Criminisi, P. Perez, K. Toyama, Object removal by exemplar based inpainting, 2003, in Proc. IEEE Conf. Computer Vision Pattern Recognition, vol. 2, pp. 721–728.
129. K. Narasimhan, V. Neha, K. Vijayarekha, An efficient automated system for detection of diabetic retinopathy from fundus images using support vector machine and Bayesian classifiers, 2012, Int. Conference ICCEET, IEEE, pp. 964–969.

130. K. Goatman, A. Fleming, S. Philip, G. J Williams, J. A Olson, P. Sharp, Detection of new vessels on the optic disc using retinal photographs, 2011, IEEE Trans. on Med. Imaging, pp. 972–979.
131. K.G. Goh, W. Hsu, Li Lee, H. Wang, ADRIS: Automatic Diabetic Retinal Image Screening system. 2001, In Medical data mining and knowledge discovery, pp. 181-210.
132. J. Lee, BCY Zee, Q. Li, Detection of neovascularization based on fractal and texture analysis with interaction effects in diabetic retinopathy, 2013, PLoS ONE journal. pone.
133. D. Selvathi, N. Balagopal, Detection of Retinal Blood Vessels Using Curvelet Transform, 2012, International Conference on Devices, Circuits and Systems, pp. 325 – 329.
134. A. Narang, G. Narang, S. Singh, Detection of Hard Exudates in Color Retinal Fundus Images Using Support Vector Machine Classifier, 2013, Int. Congress on Image and Signal Processing, 6th International Congress on Image and Signal Processing, vol. 2, pp. 964 – 968.
135. M. Jahiruzzaman, A. Hossain, Detection and classification of diabetic retinopathy using K-means clustering fuzzy logic, 2015, Int. Conf. Comp. Info. Tech. IEEE, pp. 534 – 538.
136. H. Narasimha-Iyer, Roysam, Stewart, Tanenbaum, Robust detection and classification of longitudinal changes in color retinal fundus images for monitoring diabetic retinopathy, 2006, IEEE Transaction Biomed Engineering, 53(6), pp. 1084-98.
137. H. Narasimha-Iyer, A. Roysam, C. Stewart, et al., Integrated analysis of vascular and non-vascular changes from color fundus images, 2007, IEEE Tran. Biomed Engg, 54(8), pp. 1436-45.
138. J. Soares, J. Leandro, R. Cesar, Retinal Vessel Segmentation using the 2D Gabor wavelet and supervised Classification, 2006, IEEE Trans. Med Img. Vol. 25, 9, pp. 1214 – 1222.
139. N. Ian, M. Patricia, R. Winder, Image registration and subtraction for visualization of change in diabetic retinopathy screening, 2006, Comp. Med. Imaging and Graphics 139–145.
140. S. Morales, V. Naranjo, J. Angulo, A. Mariano, Automatic Detection of Optic Disc Based on PCA and Mathematical Morphology, 2013, IEEE Tran. Med. Imaging. vol. 32, 4, pp. 786-796.